

The Myopia Epidemic

Is There a Role for Corneal Refractive Therapy?

Brien A. Holden, O.A.M., Ph.D., D.Sc.

Myopia is the leading cause of vision loss worldwide, effecting at least 1.6 million people—and these numbers will continue to grow. It is estimated that by 2020, myopia will effect 2.5 billion people, making the global impact of visual impairment enormous. More than half of ethnic Chinese children 11–12 years old in Singapore, Hong Kong, and Taiwan are myopic, and by the time these children reach 17 to 18 years of age, the rate of myopia will be close to 90% (Fig. 1).

Myopia is a serious health problem because it is irreversible, often bilateral, and affects individuals in their most productive years. High myopia (>6.00 D) can lead to a decrease in quality of life and an increased risk of complications, including cataract, glaucoma, and retinal detachment. In addition, the duration of blindness caused by complications associated with myopia can last for many years, with blindness caused by myopic retinopathy lasting for up to 17 years, diabetes and age-related maculopathy lasting up to 5 years, and glaucoma lasting 10 years.

In children, the statistics are particularly worrying. Not only is there a high percentage of blindness caused by refractive error, but data from the Refractive Error Studies in Children show that there is a very high degree of uncorrected refractive error in children from Chile, Nepal, India, and China (Table 1). The burden of uncorrected refractive error is also high in adults from developed countries, with uncorrected refractive error being responsible for 25% of functional blindness (<6/60) and 56% of visual impairment in a population of Australian adults.¹

WHAT CAN CORNEAL REFRACTIVE THERAPY (CRT) OFFER?

Patients with myopia need a refractive device or procedure that offers good vision, comfort, safety, and convenience. The preferred option for myopia would ultimately be a permanent method of correcting myopia in adults and a way of stopping or slowing the progression in children. Currently, children with myopia can anticipate a lifetime of vision correction with contact lenses or spectacles. Although laser surgery can provide permanent vision

correction, it is invasive, the effects are irreversible, and not even the most adventurous surgeons would tackle the eyes of a growing 7-year-old. Therapeutic drugs such as pirenzepine, rigid gas-permeable lenses, and progressive spectacles only have small (but statistically significant) effects.

The combination of reverse geometry lenses with more highly oxygen-permeable lens materials has revolutionized CRT for the reduction of myopia. For example, a prospective randomized study by Tahhan et al.² of four currently marketed reverse geometry lenses for overnight orthokeratology in young adults has shown that all were effective in reducing myopia, despite different fitting designs and methods (Fig. 2). Lenses were fit according to the manufacturers' fitting guidelines, and biomicroscopy, unaided visual acuity, subjective refraction, best-corrected visual acuity at high and low contrast and high and low illumination, corneal topography, and subjective rating data were collected. Between 1 week and 1 month there was a significant improvement in subjective ratings of quality of day and night vision ($P < 0.05$), but no significant change in the objective measures. No significant ocular adverse events were observed during the trial.

CRT lenses work by inducing central corneal flattening and midperipheral steepening, with much of these changes caused by epithelial thinning and thickening, respectively, but it is likely that the pressure variation on the eye from CRT lenses has effects on the whole anterior segment. After overnight wear, up to 5% thinning of the central cornea occurs.³

The future of CRT, however, will not be based on how effective the procedure is but what the risk will be for the wearer. Case contamination and overnight wear of contact lenses are known risk factors for contact lens-induced microbial keratitis. A central issue

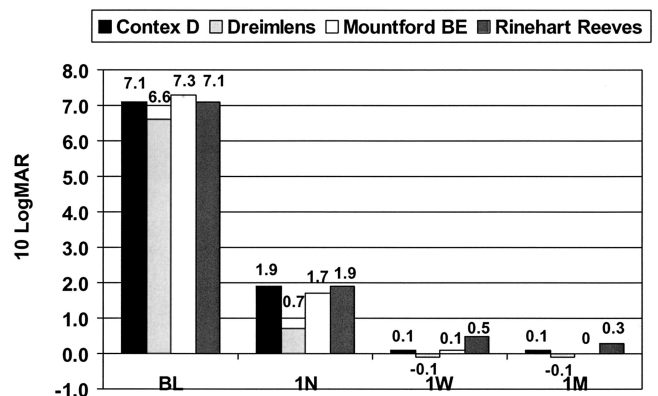


FIG. 1. Increasing rate of myopia in school-aged children in Taiwan. Data summarized from references ¹¹ and ¹².

Cornea and Contact Lens Research Unit, School of Optometry and Vision Science, and The Cooperative Research Center for Eye Research and Technology, University of New South Wales, Sydney, Australia

Address correspondence and reprint requests to B. Holden, Cornea and Contact Lens Research Unit, School of Optometry and Vision Science, and The Cooperative Research Center for Eye Research and Technology, University of New South Wales, Sydney, Australia

Accepted April 29, 2004.

DOI: 10.1097/01.ICL.0000143370.22658.E5

TABLE 1. Refractive Error (RE) in Children

Country	Blindness caused by RE (<6/60 in better eye) (%)	Visual impairment caused by RE (<6/12 in better eye) (%)	RE uncorrected on presentation (%)	Source
Chile	63	55	46	Maul et al., 2000 ¹³
Nepal	22	86	92	Pokharel et al., 2000 ¹⁴
Urban India	77	83	49	Murthy et al., 2002 ¹⁵
Rural India	38	66	86	Dandona et al., 2002 ¹⁶
China	75	93	58	Zhao et al., 2002 ¹⁷

is whether overnight epithelial pressure compromises further patient safety. To date, there have been a number of well-publicized cases of microbial keratitis in children undergoing CRT. Young et al.⁴ reported six cases in children aged between 9 and 14 years of age, where all resulted in loss of best corrected visual acuity. Five of the six cases were culture positive for *Pseudomonas aeruginosa*. However, this report did not describe whether the lenses worn by the subjects were designed for CRT, nor was it clear whether the lenses worn were made from highly oxygen transmissible materials or whether they had been properly fitted. Hutchinson et al.⁵ has reported two cases of microbial keratitis leading to permanent loss of best corrected visual acuity in Australia. *P. aeruginosa* was isolated from one case and *Acanthamoeba* from the other. Although these cases are of serious concern, it is not clear what the incidence of infection with CRT is using highly oxygen-permeable materials. John Mountford from Australia has fit 1,300 patients with overnight reverse geometry lenses since 1993 and has seen two cases of microbial keratitis. Infiltration in both cases occurred the midperiphery and were associated with noncompliance (John Mountford, personal communication, 2004).

Fundamental studies, such as that of Ladage et al.⁶ concerning overnight orthokeratology and the potential for an increase in the binding of *P. aeruginosa* to rabbit epithelial cells using highly oxygen-permeable rigid materials, are critically important to our ability to assess risk.

What Are the Risk Factors for Microbial Keratitis with CRT?

Contact lens-associated microbial keratitis is caused by a combination of factors, including bacterial contamination of lenses and lens storage cases, the bacteria-hospitable closed eye environment, and hypoxia-associated reduced resistance of the cornea. An additional key factor with CRT is the pressure-induced epithelial changes. Hygienic daytime storage of lenses is absolutely essential

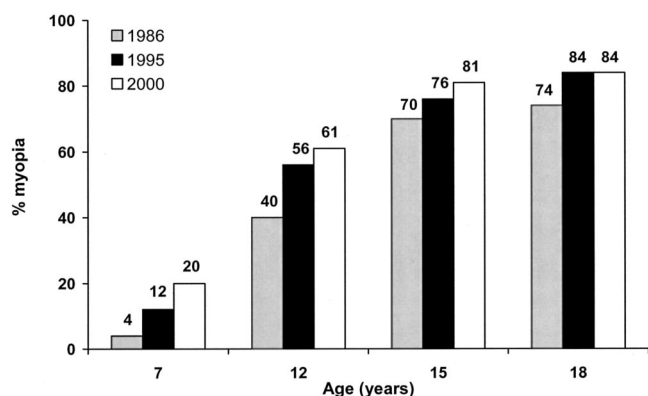


FIG. 2. Visual performance of four currently marketed reverse geometry lenses for overnight orthokeratology in young adults. Adapted from reference 2.

if risk is to be minimized, and practitioners should be emphatic that patients use a good care system and effective hygiene practices.

Can CRT Arrest the Progression of Myopia?

CRT is effective for temporarily improving unaided visual acuity and reducing myopia in young adults—but is there potential for this procedure to offer something more?

The prevalence of myopia rapidly increases in children after about 8 years of age. Therefore, to be effective in preventing the progression of myopia in children, an intervention needs to be applied at an early age. Myopia can be induced in young animal models by hyperopic defocus of the animal’s visual image, causing compensatory increases in axial length. Theoretically therefore, any corrective device that delivers clear and sharp images on the retina at all times should stop the eye from elongating. Most spectacle or contact lens interventions are ineffective because their optics are not optimized for sharp images at all distances and/or because noncompliance with, for example, the wear of progressive addition spectacles prevents children from receiving clear ongoing images. Two large, randomized, clinical trials—the COMET study⁷ (using progressive addition spectacles) and a study with rigid gas-permeable lenses⁸—show small effects on the progression of myopia in children. In addition, the small effect of gas-permeable lenses on slowing myopia could not be differentiated from the effects of corneal flattening seen with orthokeratology.

More recently, the Children’s Overnight Orthokeratology Investigation (COOKI) pilot study⁹ aimed to assess the effect of orthokeratology on the progression of myopia and to investigate the safety and efficacy of this procedure. Walline et al.⁹ followed twenty-nine 8- to 11-year-old children for 6 months and found that overnight corneal reshaping is a safe and efficacious means of temporarily reducing myopia in children. Cho et al.¹⁰ have also reported interesting findings on corneal refractive therapy subjects followed for 12 months compared with spectacle-wearing controls. Their study indicated that corneal refractive therapy may actually slow axial growth, providing a useful method for slowing myopia. The mean increase in axial length was significantly less in the orthokeratology group (0.14 ± 0.19 mm) compared with the control group (0.35 ± 0.17 mm), indicating that the effects seen are not solely caused by corneal flattening. However, more studies are needed before these preliminary results can be confirmed.

CONCLUSIONS

The future of corneal refractive therapy depends on best practice systems that include optimal lens designs, excellent wearer management, and appropriate use of lens care products. Contact lenses have the potential to offer safe, comfortable, and effective vision correction with long-term wearability.

REFERENCES

1. Taylor H, Livingston P, Stanislavsky Y, et al. Visual impairment in Australia: distance visual acuity, near vision, and visual field findings of the Melbourne Vision Impairment Unit. *Am J Ophthalmol* 1997; 123:328–337.
2. Tahhan N, Du Toit R, Papas E, et al. Comparison of reverse-geometry lens designs for overnight orthokeratology. *Optom Vis Sci* 2003;80: 796–804.
3. Wang J, Fonn D, Simpson T, et al. Topographical thickness of the epithelium and total cornea after overnight wear of reverse-geometry rigid contact lenses for myopia reduction. *Invest Ophthalmol Vis Sci* 2003;44:4742–4746.
4. Young A, Leung A, Cheng L, et al. Orthokeratology lens related corneal ulcers in children: a case series. *Ophthalmology* 2004;111: 590–595.
5. Hutchinson K, Apel A. Infectious keratitis in orthokeratology. *Clin Exper Ophthalmol* 2003;30:49–51.
6. Ladage P, Yamamoto, N, Robertson D, et al. *Pseudomonas aeruginosa* corneal binding after 24-hour orthokeratology lens wear. *CLAO J* 2004;30:173–178.
7. Gwiazda J, Hyman L, Hussein M, et al. A randomized clinical trial of progressive addition lenses versus single vision lenses on the progression of myopia in children. *Invest Ophthalmol Vis Sci* 2003;44:1492–1500.
8. Katz J, Schein OD, Levy B, et al. A randomized trial of rigid gas permeable contact lenses to reduce progression of children's myopia. *Am J Ophthalmol* 2003;136:82–90.
9. Walline J, Rah M, Jones L. The children's overnight orthokeratology investigation (COOKI) pilot study. *Optom Vis Sci* 2004;81:407–413.
10. Cho P. Ocular changes and myopia progression after 12 months orthokeratology lens wear. Presented at the 9th International Conference on Myopia, Hong Kong and Guangzhou, China, November 10–14th, 2002.
11. Lin LL, Shih YF, Tsai CB, et al. Epidemiologic study of ocular refraction among schoolchildren in Taiwan in 1995. *Optom Vis Sci* 1999;76:275–281.
12. Lin LL, Shih YF, Hsiao CK, et al. Epidemiologic study of the prevalence and severity of myopia among schoolchildren in Taiwan in 2000. *J Formos Med Assoc* 2001;100:684–691.
13. Maul E, Barroso S, Munoz SR, et al. Refractive Error Study in Children: results from La Florida, Chile. *Am J Ophthalmol* 2000;129: 445–454.
14. Pokharel GP, Negrel AD, Munoz SR, et al. Refractive Error Study in Children: results from Mechi Zone, Nepal. *Am J Ophthalmol* 2000; 129:436–444.
15. Murthy GV, Gupta SK, Ellwein LB, et al. Refractive error in children in an urban population in New Delhi. *Invest Ophthalmol Vis Sci* 2002;43:623–631.
16. Dandona R, Dandona L, Srinivas M, et al. Refractive error in children in a rural population in India. *Invest Ophthalmol Vis Sci* 2002;43: 615–622.
17. Zhao J, Mao J, Luo R, et al. The progression of refractive error in school-age children: Shunyi district, China. *Am J Ophthalmol* 2002; 134:735–743.